

Anal cancer: ESMO-ESSO-ESTRO Clinical Practice Guidelines for diagnosis, treatment and follow-up[†]

R. Glynne-Jones¹, P. J. Nilsson², C. Aschele³, V. Goh⁴, D. Peiffert⁵, A. Cervantes⁶ & D. Arnold^{7*}

¹Centre for Cancer Treatment, Mount Vernon Hospital, Northwood, Middlesex, UK; ²Department of Molecular Medicine and Surgery, Karolinska Institutet and Center for Surgical Gastroenterology, Karolinska University Hospital, Stockholm, Sweden; ³Medical Oncology and Hematology, Felettino Hospital, La Spezia, Italy; ⁴Division of Imaging Sciences and Biomedical Engineering, King's College London, London, UK; ⁵Department of Radiotherapy, Centre Alexis Vautrin, Vandoeuvre-lès-Nancy, France; ⁶Department of Hematology and Medical Oncology, INCLIVA, University of Valencia, Valencia, Spain; ⁷Klinik für Tumorbologie, Freiburg, Germany

aetiology

Squamous cell carcinoma of the anus (SCCA) is strongly associated with human papillomavirus (HPV) infection which represents the causative agent in 80%–85% of patients (usually from HPV16 or HPV18 subtypes in Europe) as is its precursor lesion anal intra-epithelial neoplasia (AIN) 3. Factors increasing the risk of HPV infection and/or modulating host response and the persistence of this infection appear to affect the epidemiology of this tumour. Anal intercourse and a high lifetime number of sexual partners increase the risk of persistent HPV infection in men and women, leading eventually to malignancy. Other important risk factors include human immunodeficiency virus (HIV), immune suppression in transplant recipients, use of immunosuppressants such as long-term corticosteroids, a history of other HPV-related cancers, autoimmune disorders, social deprivation and cigarette smoking. Cigarette smoking may also be important in the modulation/persistence of HPV infection and, hence, outcomes from treatment. Herpes simplex virus may play a secondary role in disease progression. Dietary habits, chronic inflammatory diseases and the presence of haemorrhoids do not appear to predispose to epidermoid anal cancer. Among men who have sex with men (MSM), the incidence of anal cancer is in the region of 35 per 100 000. In men who are HIV seropositive, the incidence increases to 75–135 per 100 000. The incidence is also higher among HIV seropositive women. Prolonged survival with highly active anti-retroviral treatment (HAART) is likely to lead to further increase in incidence among HIV-positive subjects.

incidence and epidemiology

Epidermoid anal cancer is a rare disease accounting for 1%–2% of digestive tract tumours and 2%–4% of colon, rectal and anal tumours. The annual incidence is 1 in 100 000, is higher in women and is increasing [1]. In Europe, ~2000 males and ~2300 females are diagnosed with anal cancer every year. Five-year survival has changed little in the last two decades. In the United States, the overall 5-year survival rates for 1994–2000 were 60% for men and 78% for women (SEER data). In Europe, 5-year survival varied between 66% (Central Europe) and 44% (Eastern Europe).

diagnosis

SCCA commonly presents with bleeding; hence, diagnosis is often delayed because bleeding is attributed to haemorrhoids. SCCA may also present with any combination of a mass, non-healing ulcer, pain, bleeding, itching, discharge, faecal incontinence and fistulae. Not uncommonly lesions are palpated first by the patient. The diagnosis of anal cancer is made on biopsy-proven histology. Small, early cancers are sometimes diagnosed serendipitously following the removal of anal tags. More advanced lesions in the distal anal canal may extend on to the skin at the anal margin. Rarely patients present with inguinal lymphadenopathy.

screening and prevention

The existence of an identified viral aetiological agent and the ability to detect pre-neoplastic lesions may allow the development of screening and prevention programmes. Vaccination of girls against oncogenic HPV is now being recommended for the prevention of cervical cancer, and a recent report indicated that up to 80% of anal cancers could also be avoided with prophylactic quadrivalent HPV vaccine (against HPV types 6, 11, 16 and 18). But currently vaccination has no role when SCCA is actually present [2].

Screening programmes using anal cytology and high-resolution anoscopy have been proposed for high-risk populations (MSM

*Correspondence to: ESMO Guidelines Working Group, ESMO Head Office, Via L. Taddei 4, CH-6962 Viganella-Lugano, Switzerland.
E-mail: clinicalguidelines@esmo.org

[†]These Guidelines were developed by the European Society for Medical Oncology (ESMO), the European Society of Surgical Oncology (ESSO) and the European Society of Radiotherapy and Oncology (ESTRO) and are published jointly in the Annals of Oncology, the European Journal of Surgical Oncology and Radiotherapy & Oncology. The three societies nominated authors to write the guidelines as well as reviewers to comment on them.

and HIV– women with a history of anal intercourse or other HPV-related anogenital malignancies) based on the achievements obtained in cervical cytology screening. However, no randomised control study has yet demonstrated the advantage of screening in these high-risk populations.

pathology/molecular biology

anal intra-epithelial neoplasia

Anal cancer may arise from a precursor dysplastic lesion—AIN—also known as anal squamous intra-epithelial lesions. The prevalence of AIN in the general population is low, but higher in 30%–40% of MSMs. Progression from AIN 1 and AIN 2 to AIN 3 is uncommon, as is progression from AIN 3 to invasive malignancy in immunocompetent patients, but appears more likely in immunosuppressed patients, and is influenced by HIV seropositivity, low CD4 count and serotype of HPV infection.

HPV-associated tumours usually retain wild-type *P53*, and this explains why patients with HPV-associated tumours respond well to concurrent chemoradiotherapy. Data on the interaction with wild-type *P53* in current or former cigarette smokers, as in head and neck cancer, are lacking.

Both synchronous and metachronous HPV-related vaginal and cervical intra-epithelial and malignant squamous lesions are frequent and should be screened for in younger women.

histology

Histological confirmation is mandatory as other histologies are possible including adenocarcinoma, melanoma, gastrointestinal

stromal tumours, poorly differentiated neuroendocrine tumours and lymphoma.

Tumours of the anal margin are generally well differentiated and often occur in men, in contrast to canal tumours which are normally poorly differentiated and more common in women. Histological grading is subject to inter-observer variability, and considerable heterogeneity is seen in larger tumours. High-grade tumours have been thought to have a worse prognosis, but this has not been confirmed in multivariate analysis. Histological sub-classifications of basaloid, transitional, spheroidal and cloacogenic cell cancers have no additional confirmed bearing on management. Some authors report that a basaloid histological subtype has a higher risk of developing metastatic disease. The biology and prognosis of keratinising and non-keratinising tumours of the anal canal also appear to be similar. Verrucous carcinomas are a variant and are sometimes described as giant condylomas or Buschke–Lowenstein tumours, which may have a better prognosis than SCCA, for whom some consider surgery the best option.

anatomy and lymphatic drainage

Lymph node involvement at diagnosis is observed in 30%–40% of cases while systemic spread is uncommon with distant extra-pelvic metastases recorded in 5%–8% at onset.

The anal canal extends from the anorectal junction to the anal margin (see Figure 1).

Useful palpable landmarks are the puborectal sling and the inter-sphincteric groove, respectively. The columnar, or cylindrical, epithelium of the rectum extends to about 1 cm above the dentate line where the anal transitional zone begins. Below the dentate line, the epithelium is all squamous. The anal margin is

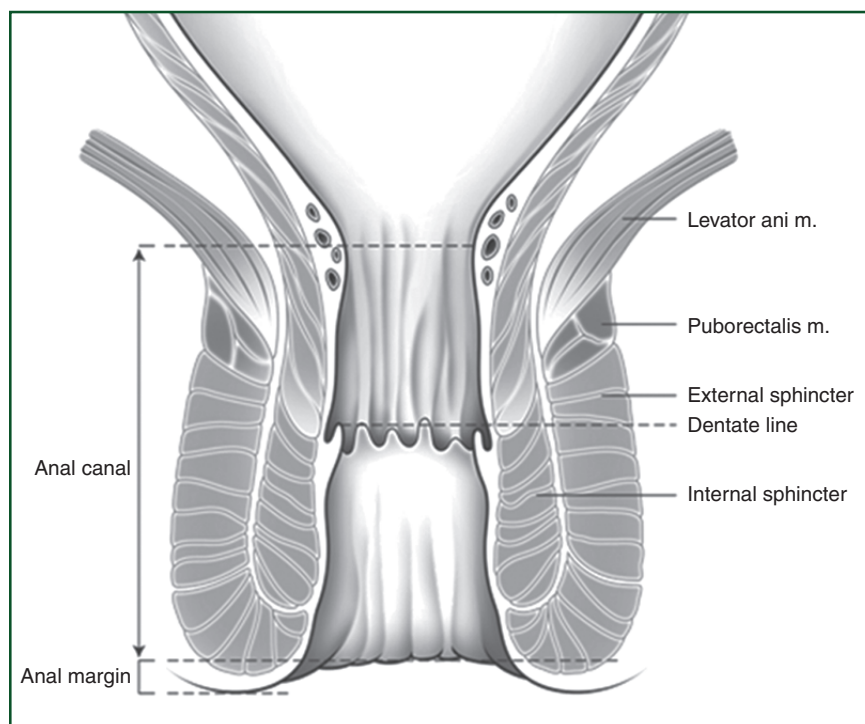


Figure 1. Anatomy of the anal region.

the pigmented skin immediately surrounding the anal orifice, extending laterally to a radius of ~5 cm. In practice, at diagnosis, the precise point of origin is often uncertain, and the distinction between anal canal and anal margin tumour is often difficult, if not impossible. Hence, some have classified into three distinct regions—i.e. intra-anal, perianal (visualised with gentle traction on the buttocks) and skin tumours (beyond a 5 cm radius from the anal opening).

Proximally lymphatic drainage is to perirectal nodes along the inferior mesenteric artery. Immediately above the dentate line, drainage is to internal pudendal nodes, and to the internal iliac system. Infra-dentate and perianal skin drains to the inguinal, femoral and external iliac nodes.

clinical assessment

A relevant history is required to elicit symptoms, other relevant medical conditions, current medications and predisposing factors, which should be documented. Examination should include digital rectal examination (DRE) to examine the anal lesion and perirectal nodal involvement and, in women (particularly with low anteriorly placed tumours), a vaginal examination to determine the site and size of the primary tumour, vaginal/vaginal septal involvement, mucosal involvement and exophytic or ulcerative tumour or the presence of a fistula (Table 3). Vaginal involvement may require the prophylactic siting of a de-functioning stoma because of the risk of an ano-rectal-vaginal fistula. However, since only 50% of initial colostomies are reversed, this decision should be weighed carefully. Palpation of the inguinal nodes is important, particularly those superficial inguinal nodes, medial and close to the pubis.

Proctoscopy by a specialist surgeon or radiation oncologist and, if painful, examination under anaesthesia (EUA) may be appropriate to facilitate biopsy (Table 3). It is also easier to determine anatomical relations to surrounding structures and to allow accurate clinical staging. It is advantageous if the treating radiation oncologist is present during this EUA to document precise measurements, as these are often critical for later target volume delineation in treatment planning.

Colonoscopy is not required to assess pathology in the proximal bowel, because synchronous lesions are not reported for SCCA.

staging

With an indolent natural history and a low rate of distant metastases, anal cancer is usually amenable to locoregional treatment.

Imaging should include magnetic resonance imaging (MRI) (Table 3) of the pelvis or, if not available, endo-anal ultrasound (EUS). Distant metastases can be assessed with computed tomography (CT) of the thorax and abdomen. MRI provides excellent contrast and spatial resolution, providing information on tumour size, local extent and spread, and invasion of adjacent organs and more accurate nodal involvement [3].

Accurate assessment of tumour size and depth of mural invasion is possible with EUS, due to excellent spatial detail but is best reserved for small T1 lesions as the small field-of-view limits assessment of regional lymph nodes and infiltration of structures beyond the anal canal.

Positron emission tomography (PET)/CT with [¹⁸F]fluorodeoxyglucose (FDG-PET/CT) has a high sensitivity in identifying involved lymph nodes, as the majority of anal carcinomas are FDG-avid. Several studies have shown that FDG-PET/CT can alter staging in ~20% of cases, with a trend towards up-staging, and can alter treatment intent in ~3%–5% of cases. The main impact of FDG-PET/CT on therapy stems from its high sensitivity in identifying involved lymph nodes and influencing radiation therapy planning by defining sites of metabolically active tumour. Therefore, FDG-PET has been recommended in the current USA National Comprehensive Cancer Network treatment recommendations.

The tumour–node–metastasis (TNM) clinical staging system is based on accurate assessment of size (T stage), regional lymph node involvement (N) and metastatic spread (M). Nodal status is based on the distance from the primary site rather than the number of nodes involved, see Table 1. Nodal involvement of anal canal lesions differs from that of anal margin tumours.

Biopsy by needle aspiration biopsy is usually only carried out for clinically palpable inguinal nodes or those enlarged >10 mm on CT or MRI. Sentinel lymph node biopsy can reveal micrometastatic spread of disease, and may be more accurate than diagnostic imaging, but has not been properly evaluated.

Squamous cell carcinoma antigen (SCCAg) is a serum tumour marker expressed by carcinomas of the anal canal, and may be related to tumour stage and/or nodal status, but its clinical utility in diagnosis and follow-up remains controversial.

risk assessment

Anal cancers occur rarely, and factors influencing outcome and long-term survival have proved difficult to study with multivariate analysis. Several factors are relevant to initial decision-making (Table 2). The European Organisation for Research and Treatment of Cancer (EORTC)-22861 study demonstrated that skin ulceration, nodal involvement and male sex were independent variables associated with locoregional failure rate (LRF) and overall survival (OS) [5]. The Radiation Therapy Oncology Group (RTOG) 9811 analysis supported the EORTC previously reported factors (clinically involved nodes and male sex), and also established tumour diameter >5 cm as an independent variable predicting disease-free survival (DFS) and OS. The ACT I analysis showed that palpable inguinal nodal status and gender are independently prognostic for OS, LRF and anal cancer death (ACD). In addition, after adjusting for sex and nodal status, presenting haemoglobin was a further prognostic factor for ACD. HIV testing is recommended in any patient with a lifestyle that puts them at risk of contracting HIV infections. Some argue that all patients with anal cancer should be screened for HIV [6].

Before the widespread use of HAART, HIV-positive patients were considered to have enhanced toxicity from chemoradiation (CRT), particularly in patients with low CD4 counts <200/mm³ which may impact on compliance [7]. Such patients were excluded from the randomised trials. More recent evidence suggests similar outcomes in HIV-positive patients treated with HAART in terms of complete response and survival to HIV-negative patients [8, 9]. However, we have no randomised data to guide best practice in immuno-compromised and HIV-positive patients.

Table 1. TNM staging. American Joint Committee on Cancer/Union for International Cancer Control (AJCC/UICC) seventh edition TNM clinical and pathological classification of anal cancer

Primary tumour (T)			
TX	Primary tumour cannot be assessed.		
T0	No evidence of primary tumour.		
Tis	Carcinoma <i>in situ</i> (i.e. Bowen disease, high-grade squamous intra-epithelial lesion, and anal intra-epithelial neoplasia II–III.)		
T1	Tumour ≤2 cm in greatest dimension.		
T2	Tumour >2 cm but ≤5 cm in greatest dimension.		
T3	Tumour >5 cm in greatest dimension.		
T4	Tumour of any size invades adjacent organ(s), e.g. vagina, urethra, and bladder.		
Regional lymph nodes (N)			
NX	Regional lymph nodes cannot be assessed.		
N0	No regional lymph node metastasis.		
N1	Metastases in perirectal lymph node(s).		
N2	Metastases in unilateral internal iliac and/or inguinal lymph node(s).		
N3	Metastases in perirectal and inguinal lymph nodes and/or bilateral internal iliac and/or inguinal lymph nodes.		
Distant metastasis (M)			
M0	No distant metastasis.		
M1	Distant metastasis.		
Anatomic stage/prognostic groups			
Stage	T	N	M
0	Tis	N0	M0
I	T1	N0	M0
II	T2	N0	M0
	T3	N0	M0
IIIA	T1	N1	M0
	T2	N1	M0
	T3	N1	M0
	T4	N0	M0
IIIB	T4	N1	M0
	Any T	N2	M0
	Any T	N3	M0
IV	Any T	Any N	M1

In ref. [4], used with the permission of the American Joint Committee on Cancer (AJCC), Chicago, IL, USA. The original source for this material is the AJCC Cancer Staging Handbook, Seventh Edition (2010) published by Springer Science and Business Media LLC, www.springer.com.

Every effort should be made to ensure patients stop smoking before therapy, because smoking may worsen acute toxicity during treatment and enhance late toxicity.

initial management of local and locoregional disease

The primary aim of treatment is to achieve cure with locoregional control and preservation of anal function, with the best

Table 2. Factors to consider in treatment decision-making for anal cancer

Disease-related factors	Patient-related factors	Other
Clinical and radiological TNM stage	Patient preferences	Local expertise (brachytherapy etc.)
Site of tumour (margin, canal, rectal)	Biological age/renal function/Charlson geriatric assessment	Geriatricians with interest in oncology
Extent of tumour, i.e. involvement of vagina (risk of fistulation) in addition to size	Co-morbidities/current medications and performance status	
Response to treatment (early and at 26 weeks)	Socioeconomic and psychological factors/social support	
Need for symptom control	Severity of initial symptoms	Specialist palliative care

TNM, tumour–node–metastasis.

possible quality of life. Treatment dramatically differs from adenocarcinomas of the lower rectum.

Combinations of 5-fluorouracil (5-FU)-based CRT and other cytotoxic agents [mainly mitomycin C (MMC)] have been established as the standard of care, leading to complete tumour regression in 80%–90% of patients, with locoregional failures of ~15%. A multidisciplinary approach is mandatory, involving radiation therapists, medical oncologists, surgeons, radiologists and pathologists. The role of surgery as a salvage treatment is accepted. Assessment and treatment should be carried out in specialised centres treating a high number of patients as early as possible in the clinical diagnosis (Table 3). To date, the limited evidence from only six randomised trials [5, 10–14], the rarity of the cancer and the different behaviour/natural history depending on the predominant site of origin (the anal margin, anal canal or above the dentate line) provide limited direction for any individual oncologist (Table 4). An example of treatment of anal cancer is shown in Figure 2.

surgery as primary treatment

Until the mid-1980s, radical surgery was the cornerstone of treatment. However, following publications from the 1970s on combined modality therapy, surgery as the primary therapeutic option has generally been abandoned.

Still today, smaller lesions (<2 cm in diameter), involving the anal margin and not poorly differentiated may be treated by primary surgery in the form of a local excision provided adequate margins (>5 mm) can be obtained without

Table 3. Diagnostic work-up

Mandatory	Optional but often recommended	Optional
Biopsy to confirm diagnosis		
Full medical history	HIV test	
Full clinical body exam	Needle aspiration groin nodes	
Digital rectal examination	Examination under anaesthesia	
Blood tests including renal function		
Proctoscopy		Colonoscopy
Pelvic MRI		Endo-anal ultrasound
CT thorax/abdomen	PET/CT	
Assessment of genital tract in females for CIN/VIN		Assessment by geriatrician

CIN, cervical intra-epithelial neoplasia; VIN, vulval intra-epithelial neoplasia; MRI, magnetic resonance imaging; HIV, human immunodeficiency virus; CT, computed tomography; PET, positron emission tomography.

Table 4. Stage and site-based treatment

Anal canal	
Surgery (radical or local excision) generally contra-indicated as primary treatment option	
Stage I	Standard-dose RT, infused 5-FU and mitomycin C (stage group under-represented in randomised studies)
	Low-dose RT, infused FU, and mitomycin C (no data from randomised studies)
Stage II–III	Standard-dose RT, infused FU, and mitomycin C (evidence from multiple randomised studies)
Stage IV	5-FU and cisplatin, carboplatin/taxol, or possibly irinotecan/cetuximab
Anal margin	
Stage I, well differentiated:	Local excision (re-excision or chemoradiation if involved/close margins)
Stage II–III	Standard-dose RT, infused 5-FU and mitomycin C
Stage IV	5-FU and cisplatin, or carboplatin/taxol

5-FU, 5-fluorouracil; RT, radiotherapy.

compromising sphincter function [IV, C]. Local excision has not been shown to be efficacious for small tumours in the anal canal and is contra-indicated. Although more extensive and poorly differentiated lesions have a greater risk of being lymph node positive, it is important to do proper clinical and radiological staging also of smaller lesions in order to rule out the presence of positive nodes as this is a contra-indication to local excision. Piecemeal resections render assessment of resection margins in the specimen impossible and should not be carried out.

In case of inadequate margins or R1 resection (occurs sometimes after a resection of 'anal tags' or 'haemorrhoids'), a further local excision may be considered after adequate staging, and clinical assessment provided R0 resection can be achieved. However, it is recommended that all patients having undergone a local resection, irrespective of resection margin, should be discussed by an appropriate multidisciplinary team (MDT) to facilitate decisions regarding re-excision or definitive CRT.

Until the introduction of definitive CRT, abdomino-perineal excision (APE) was recommended for all other tumours (except those amenable to local excision). Primary APE was associated with local failure in up to half of cases, and 5-year survival rates in the region of 50%–70% were reported [IV, C]. Today,

primary APE may be offered to patients previously irradiated in the pelvic region.

chemoradiation

Evidence supporting the effectiveness of CRT as a radical treatment has been provided by multiple phase II and case-series studies. Subsequent randomised trials have established the optimal regimen, although no individual randomised study has directly compared surgery versus CRT. Recommendations are based on the results of the phase II and six randomised phase III trials (EORTC 22861, UKCCCR ACT I, RTOG 87-04, RTOG 98-11, ACCORD-03, CRUK ACT II). 5-FU with MMC combined with radiotherapy are generally recommended, rather than 5-FU and cisplatin, MMC and cisplatin, any single drug or any combination of three drugs [I, A].

Stage I patients represent only 10%–15% in the majority of randomised CRT trials, hence application of overall data to T1 tumours is limited. However, for small tumours (T1), some investigators have used external beam radiotherapy alone, followed by a small volume boost either with photons, electrons or interstitial implantation.

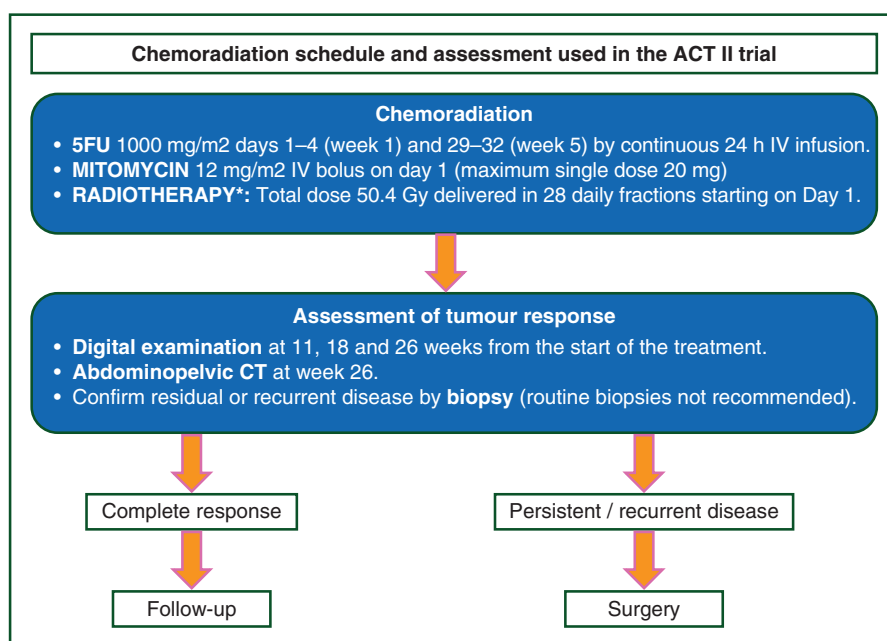


Figure 2. Chemoradiation schedule used as a control arm in the ACT II trial as a working example of treatment of anal cancer [14]. *Note that the radiotherapy schedule should not be considered standard of care.

In contrast, early investigators [15, 16] reported that CRT, with the addition of MMC to 5-FU, demonstrated excellent local control in small tumours (<4 cm). Sequential phase II studies with CRT have shown the efficacy of relatively low total radiation doses (30–50 Gy) in combination with 5-FU and MMC.

Randomised, controlled studies in Europe have demonstrated that synchronous CRT, as the primary modality, is superior to radiotherapy alone. The RTOG phase III study compared 5-FU with 5-FU and MMC in combination with radiotherapy (median dose 48 Gy), and did not use a planned gap, but boosted poor responders with a further 9 Gy. This study confirmed the superiority of the combination of MMC and 5-FU.

It remains unclear whether increasing the radiation dose to >50 Gy in patients with locally advanced anal cancer receiving combined modality therapy will improve the results—particularly in good responders.

The second generation of randomised studies investigated the role of cisplatin as a replacement of MMC in combination with 5-FU and radiation. In these studies, cisplatin and FU were also used before or after CRT as neo-adjuvant or maintenance treatment, respectively.

The results of these studies indicate that:

- (1) Cisplatin in combination with infused 5-FU and radiation does not improve either complete response rates or local control compared with MMC and does not reduce overall toxicity (but results in less myelotoxicity);
- (2) Neo-adjuvant chemotherapy before CRT has not improved either locoregional or distant control, and colostomy-free survival (CFS) is significantly worse [5, 10, 12]. More mature data suggest that local control and DFS are also worse [12]. Neo-adjuvant chemotherapy should not be given outside clinical trials [1].

- (3) Additional maintenance/consolidation chemotherapy following CRT has not impacted on local control, DFS or OS [11].

The 2-month treatment gap used in early trials, which aimed to allow time for tumour shrinkage and recovery of acute pelvic toxicity, has now been abandoned (consensus of experts).

Although randomised trials have not been carried out, the evidence from phase II studies and data extrapolated from randomised trials in rectal cancer suggest that capecitabine might be considered as an alternative to infused 5-FU.

radiotherapy technique and treatment fields

The patient is usually treated in the supine position, although there are some exceptions where prone positioning for very exophytic tumours may be better with bolus applied.

Uninterrupted treatment, avoiding a gap, is considered radiobiologically the most effective treatment [III]. Doses of at least 45–50 Gy without a treatment gap are recommended for T1–2 N0. Higher doses may be required for more advanced tumours, particularly if a planned treatment gap is used. Boost doses to the primary tumour have usually ranged from 15 to 25 Gy, with higher doses applied for observed poor response. Hence, currently, it is not possible to make a definitive recommendation (based on inter-trial comparisons of differing dose fractionations with or without a treatment gap) on the requirement for, the form (external beam or brachytherapy) or the appropriate doses for a boost after 50 Gy.

Dogmatic definition of treatment fields is also beyond the scope of this article. There are significant differences in approach within Europe but, in general, treatment should aim to

encompass the primary tumour and any sites of likely nodal involvement within the high-dose volume.

Delivery of radiotherapy in anal cancer is complex because of the varying size and shape of the target volume, and the proximity to dose-sensitive critical structures, such as small bowel, rectum, bladder femoral heads, perineum and external genitalia. These structures often received high doses of radiation with conventional parallel opposed techniques. The first randomised trials have mainly relied on 2D-based radiation therapy planning in which anatomic (bony) landmarks were used to guide field design using orthogonal X-ray images. More recently, conformal (CT-guided or 3D) radiotherapy-based treatments have been used, which allow the radiation oncologist to identify normal as well as target soft-tissue structures on axial CT images, and have led to improved treatment accuracy and delivery.

Recent randomised trials [5, 11, 12] have shown good local control in early-stage tumours. However, radiotherapy techniques that have relied on anterior–posterior/posterior–anterior (APPA) fields may be associated with severe acute toxicity causing excessive breaks in treatment leading to treatment failure, and also late radiation morbidity.

Overall grade 3 and 4 acute toxicity during CRT in ACT II and RTOG 9811 was similar in both arms, i.e. 72% and 74%, respectively. The most common grade 3/4 adverse events were; skin, haematological and gastrointestinal [5, 11]. More conformal treatment strategies such as intensity-modulated radiotherapy (IMRT) spare organs at risk, reduce toxicity and may allow full or even escalated doses to be achieved within a shorter overall treatment time. Hence, IMRT or volumetric modulated arc therapy is currently recommended for the treatment of anal cancer, setting strict radiation dose constraints to normal organs.

Several ‘proof-of-principle’ studies of IMRT in anal canal carcinoma have reported significant reduction in the doses delivered to the bowel, bladder and genitalia/perineal skin. Prospective phase II multicentre studies (RTOG 0529) have shown that IMRT is deliverable in a multicentre setting [17, 18], with a reduction in toxicity when contrasted with the best arm of the RTOG 9811 trial. The efficacy of doses <1.8 Gy per day are assumed, but data are inadequate.

Australasian planning guidelines interpret CT definitions and provide a high-resolution atlas for contouring gross disease and organs at risk [19], which complements the existing RTOG elective nodal anorectal atlas [20]. The descriptions of the elective target volumes or compartments are useful and reproducible.

The inguinal nodes should be formally included in the radiation fields in the majority of cases, even in the absence of clearly demonstrable involvement. The incidence of nodal involvement increases with increasing primary tumour size and is at least 20% in patients with T3 disease. However, some clinicians may treat clinically uninvolved inguinal nodes only in certain circumstances [e.g. T3–4 primary disease, location of primary tumour within the canal (below the dentate line), ≤1 cm from the anal orifice or if there is involvement of pelvic lymph nodes (on CT or MRI criteria)].

brachytherapy

Brachytherapy is a highly conformal treatment which is able to deliver a high dose to the primary tumour, sparing surrounding

normal tissues and the contralateral mucosa and sphincter. Expertise for iridium-192 interstitial implantation is limited to a few European institutions. Low-dose rate, high-dose rate (HDR) and pulsed dose rate brachytherapy have been tested in clinical practice. There are currently limited data on the use of HDR brachytherapy in anal cancer and lack of consensus on the optimal fractionation schedule. Curative brachytherapy as a single modality is not recommended, but may be applicable as a boost following response to CRT. Double-plane, or volume implants may be necessary, depending on the extent of the tumour, but risk late necrosis and radiation proctitis. Computerised 3D image-based treatment planning should allow optimal dose distribution.

treatment of the elderly

Although some have recommended dose reductions, omission of chemotherapy or reduction of irradiated volumes for elderly and frail patients, current data suggest that elderly patients should be treated similarly to their younger counterparts. The physiological fitness of elderly patients is increasing with longer predicted life expectancy (based upon actuarial tables). Consequently, this group of patients are at risk of significant under-treatment if treatment choices are based purely upon age. A good collaboration between geriatricians, clinical nurse specialists and radiation and medical oncologists will facilitate the delivery of radical treatment.

post-operative chemoradiation

Post-operative CRT should be considered in patients who have undergone excision of perianal skin tags where piecemeal histological assessment means that completeness of excision cannot be guaranteed, or in the case of narrow margins, when re-excision is not feasible, and for patients considered at risk of pelvic node involvement. Similar indications as for skin cancers are relevant, i.e. depth of invasion, size of tumour and the extent of the surgical margin. Other indications are local excision of anal canal lesions (which are not recommended), and in the rare cases when radical surgery has been carried out as primary treatment but the resection margin is involved. It is recommended that all such patients should be discussed by an appropriate MDT to facilitate decisions regarding re-excision or post-operative CRT.

toxicity and supportive care during radiotherapy

Patients should be assessed, and full blood counts checked weekly if MMC is used, as CRT is associated with high risks of higher grades of haematological toxicity. Patients should be informed of the negative effect of smoking before CRT. Smoking may worsen acute toxicity during treatment and lead to a poorer outcome in terms of DFS and CFS. Every effort should be made to ensure patients quit smoking before therapy.

Tolerance to treatment can be maximised with antibiotics, antifungals, anti-emetics, analgesia, skin care, advice regarding nutrition to prevent or correct weight loss and psychological support.

The recommendation for post-treatment use of vaginal dilators in sexually active females is controversial. Pre-menopausal women should be informed that menopause will ensue and

fertility will be lost, unless the ovaries are moved out of the radiation field. Hormone replacement therapy may be appropriate in those in whom an early menopause is induced. Sperm banking should be discussed before the commencement of treatment with male patients who wish to preserve fertility.

response evaluation

Anal cancers tend to regress slowly after completion of CRT treatment. DRE is the mainstay of determining complete response after treatment—defined as the absence of tumour and/or ulceration. Examination may be more informative when carried out under general anaesthesia if pain persists or response is difficult to quantify. Careful clinical inspection of the inguinal regions in addition to radiographic evaluation (with pelvic MRI and CT scans, or as a comparison of PET-CTs, if available) is also necessary. Oedema, residual fibrosis or scar tissue can be difficult to distinguish from persistent active disease. However, biopsies of persistent clinically suspicious lesions 8–12 weeks after CRT completion are not routinely recommended. Treatment-related effects may confound the pathological interpretation of post-treatment biopsies. Good radiographic partial regression can be managed by close follow-up, to confirm that (a delayed) complete regression takes place, which may take 6 months. A decision regarding salvage surgery should be deferred safely in these circumstances. Hazard ratios from the ACT II data indicate that assessment at 26 weeks is the most discriminating end point with the most significant effect on outcome, and is therefore the optimum time point for definitive assessment with a view to salvage surgery. Residual or 'recurrent' tumour must be confirmed histologically before considering proceeding to radical surgery.

MRI complements clinical assessment, and acts as a useful baseline. MRI can capture and document response, but no individual MRI feature appears predictive of eventual outcome [21]. EUS is controversial as oedema and scar tissue may be difficult to distinguish from persistent tumour.

To date, few FDG–PET/CT studies have assessed treatment response, and the timing of assessment is controversial. The benefit of PET is rather to detect residual sub-clinical pelvic or extra-pelvic/para-aortic node involvement.

prognostic factors

Prognostic factors for survival (and CFS) in anal cancer include male sex, positive lymph nodes particularly positive inguinal lymph nodes and primary tumour size >5 cm. The original EORTC 22861 trial also found that skin ulceration was prognostic for worse survival and local control. Recent multivariate analysis from the ACT I trial validated against the ACT II dataset showed that positive inguinal nodes and the male sex were prognostic for local regional failure, ACD and OS, as was haemoglobin [22]. Even in the context of HIV, patients with anal cancer who smoke also appear to have a worse OS than non-smokers.

personalised medicine

Despite intriguing developments in our understanding of the molecular biology and processes which lead to anal cancer,

there remains considerable heterogeneity in terms of outcomes, particularly for more advanced stages. Biomarkers to provide predictive and prognostic information, and to inform individualised therapies, would be helpful. Only a limited number of markers in small numbers have been analysed to date, with a variety of treatment regimens. Cytogenetic, immunohistochemical and molecular markers provide information on cancer pathogenesis, but are not sufficiently robust to guide prognosis or select treatment. Further work in randomised studies is required.

The cell cycle regulator p16 is overexpressed in high-risk HPV-related cervical cancers, which may represent a simple surrogate biomarker for identifying squamous cell carcinomas harbouring HPV DNA. Patients with moderate/strong p16 staining may achieve better response to CRT and have a lower risk of relapse than patients with absent or weak staining.

A recent systematic review examined 29 different biomarkers [23]. Tumour suppressor genes p53 and p21 were the only biomarkers which were prognostic in more than one study. Molecular biomarkers associated with HPV deregulation (i.e. p16, Ki67, MCM7, K17, K7, K2 and HPV E4) may be relevant. In an analysis of 240 patients randomised in the UKCCR ACT I anal cancer trial, the presence of mutated p53 predicted for a poorer cause-specific survival. In summary, there are no current biomarkers that consistently predict sensitivity to CRT, and more research is required to identify molecular markers.

follow-up and surveillance and long-term implications

follow-up

Patients in complete remission at 8 weeks should be evaluated every 3–6 months for a period of 2 years, and 6–12 monthly until 5 years, with clinical examination including DRE and palpation of the inguinal lymph nodes. Anoscopy or proctoscopy is an additional option, but is sometimes poorly tolerated and too painful following CRT. Some recommend MRI on a 6-monthly basis for 3 years. Suspicious progressing lesions should be biopsied. Data from ACT II suggest very few (<1%) relapses occur after 3 years, so extended imaging surveillance after this time is not recommended.

Patients tend to relapse locoregionally rather than at distant sites. Regular CT scans for metastatic surveillance outside trials remains controversial, as the evidence for benefit of resection of metastases as carried out in colorectal cancer is lacking, although anecdotally, salvage is achieved in some cases.

management of advanced/metastatic disease

Approximately 10%–20% of patients suffer distant relapse. The most common sites of metastatic spread are to the para-aortic nodes, liver, lungs and skin, which usually appear relatively late and in the context of local persistence or recurrence of disease following treatment. The prognosis in this group is poor with only 10% of patients with distant metastases surviving 2 years or more, but long-term survivors are described. Patients with small volume or isolated metastatic disease should be further discussed by an appropriate MDT, in case there are surgical or CRT options.

There is no consensus on the standard chemotherapy treatment. The choice of chemotherapy is often influenced by previously used agents in the initial CRT regimen, but regimens with good documented activity are limited and generally have produced unsatisfactory results.

Otherwise fit patients with symptomatic metastatic or recurrent disease not amenable to surgery should be considered for chemotherapy, usually with a combination of cisplatin and 5-FU. Activity is also reported for carboplatin, doxorubicin, taxanes and irinotecan ± cetuximab—or combinations of these agents. These options will be influenced by the disease-free interval, and the patient's preferences and performance status. Responses are rarely complete and usually of short duration. Currently, the international rare cancers initiative, which is a consortium of international investigators from the UK, US, Europe and Australia, has developed a multicentre international trial testing the role of carboplatin/paclitaxel against the common standard 5-FU/cisplatin.

quality of life

Data on long-term quality of life are sparse, but appear to show that patients are satisfied despite objective impairment of sphincter function. Continence and quality of life appear impaired in many patients [24, 25]. Efforts should be made to document quality of life and late effects. Population data suggest that function is poor, particularly if patients continue to smoke.

Sexual and urinary function may also be compromised. In the RTOG 9811 trial, the rate of severe long-term toxic effects was similar in both arms, 11% versus 10%, but only 5% required a colostomy for treatment-related late effects. Adverse late effects appear to relate mostly to total radiation dose received in multivariate analysis rather than the type of chemotherapy.

Information regarding treatment side-effects should be provided clearly, particularly on sexual functioning as substantial numbers of patients describe difficulty with their sex lives, with specific concerns regarding loss of libido, inability to enjoy sex and erectile dysfunction. Follow-up of issues relating to sexual dysfunction has been sub-optimal, particularly for female patients who have undergone radical pelvic radiotherapy.

There is increasing support in the literature towards the development of nurse-led, late effects/survivorship clinics for patients who have received pelvic radiotherapy. There are reports detailing the effectiveness of pelvic floor exercises and/or biofeedback training in patients who experience faecal urgency and incontinence.

salvage surgical treatment

Patients with locally persistent, progressive or recurrent disease should be considered for surgical salvage [I, A]. A very small proportion of patients may be treated by local resection. At least an abdomino-perineal excision is required in the majority of patients since achievement of a negative resection margin appears crucial. For some patients, a posterior or total pelvic exenteration is required and surgery should preferably be carried out in institutions with experience of multi-visceral resections. In addition to a positive biopsy, pre-operative local staging is mandatory and MRI provides an excellent alternative. Although distant metastases are unusual, CT scan of thorax and abdomen (or PET/CT) is advised to rule out the occurrence of such. Because the salvage operation for anal cancer involves a wider perineal resection than what is

done in rectal cancer, and surgery is carried out in a heavily irradiated area, the risk of post-operative complications, in particular involving the perineal wound, are substantial. Perineal reconstruction with musculocutaneous flaps is generally recommended and appears to reduce complication rates [26]. Persistent or progressive disease in the inguinal lymph nodes should be considered for surgery, i.e. radical groin dissection and pre- or post-operative irradiation discussed—depending on the dose distribution from the definitive CRT. Flap reconstruction may be needed in some instances when recurrence in an irradiated groin is subject to surgical salvage. Salvage surgery can achieve local pelvic control in ~60% of cases, and a 5-year survival rate of 30%–60%.

palliative care

Pain due to recurrent pelvic tumour can be extreme, and requires expertise in combinations of opiate and non-opiate pain relief, sedatives and anxiolytics. Nerve blocks and re-irradiation may be feasible. Fistula from the bladder or rectum is not uncommon and demands meticulous skin care and, rarely, surgical diversion

Table 5. Summary of recommendations

Patients with anal cancer should be managed, from diagnosis through initial treatment and subsequent surveillance, by an experienced and specialised multidisciplinary team.
Locoregional control with good quality of life and the avoidance of a permanent stoma is the primary aim of treatment.
The optimal total dose of radiation is unknown. Chemoradiation (CRT) with at least 45 Gy, infused FU and MMC remains the standard treatment of stage II or higher anal canal tumours and a boost with 15–20 Gy may be applicable, especially if chemotherapy cannot be safely delivered, leading to cure in the majority of patients.
Less intensive treatment programmes with lower doses of irradiation may be successfully used in smaller tumours or fragile patients although evidence from randomised trials is not available.
Neo-adjuvant and adjuvant chemotherapy using cisplatin has not been shown to improve outcomes (progression-free survival or OS).
CRT with 5-FU and cisplatin had similar complete response and overall toxicity when compared with 5-FU and MMC but less haematological toxicity. Any marginal benefit for cisplatin in terms of haematological toxicity is likely to be outweighed by the extra resources needed to administer cisplatin—two courses of i.v. treatment with hydration over several hours, compared with only a single dose of MMC.
Response should be assessed from 6 weeks, but data suggest that the optimal time to assess complete response may be 26 weeks, rather than 11 weeks, if surgical salvage is discussed.
Surveillance/follow-up after completion of CRT treatment has not been rigorously examined, but should focus on salvage of local failure (<10% will recur after the first 3 years following completion of chemoradiation treatment).
The techniques for surgical salvage in anal cancer are different from that carried out for rectal cancer, are associated with high morbidity, and require input from multiple surgical teams (e.g. urology and plastic reconstruction).

OS, overall survival; 5-FU, 5-fluorouracil; MMC, mitomycin C.

procedures in patients with reasonable life expectancy. Palliation of the dying patient with anal cancer is often difficult. The symptoms are often odorous and may make emotional support for the patient and family members very challenging.

conclusion

An MDT approach is essential for the optimal management of anal cancer. Despite the results of four randomised phase III trials in anal cancer, the paradigm of external beam radiation therapy with concurrent 5-FU and MMC developed over 30 years ago by Norman Nigro remains the standard of care.

As anal cancer is a rare tumour, the authors strongly believe that it is in the interest of all patients to be offered participation in a clinical trial. National and international trials in this disease site are on-going throughout Europe.

note

PubMed and Medline were searched for articles published between 1990 and June 2013. The search terms included squamous cell carcinoma, anal cancer, anal canal carcinoma, anal margin cancer, survival, diagnosis, recurrence, surgery, chemotherapy, radiotherapy, CRT and chemoradiotherapy.

Recent reviews and guidelines are available as listed in the literature.

A summary of recommendations is provided in Table 5. Levels of evidence and grades of recommendation have been applied using the system shown in Table 6. Statements without grading were considered justified standard clinical practice by the expert authors and the reviewers. The present guidelines have been formulated with the assistance of the United Kingdom National Cancer Research Institute (NCRI) multidisciplinary Anal Cancer Group.

conflict of interest

RG-J has reported that, in the last 3 years, he has received honoraria for lectures from Roche, Merck-Serono, Pfizer and Sanofi and that he has received honoraria for advisory boards from Roche, Merck-Serono, Eli Lilly and Sanofi. He also has received funding and free cetuximab from Merck-Serono for a phase I/II study integrating cetuximab into CRT in rectal cancer. He receives a supply of bevacizumab from Roche for 3 months for 60 patients in a current randomised phase II study as neo-adjuvant chemotherapy in rectal cancer. He has finally received support for attending international meetings in GI cancer from Roche, Merck-Serono and Sanofi. The other authors have reported no potential conflicts of interest.

Table 6. Levels of evidence and grades of recommendation (adapted from the Infectious Diseases Society of America–United States Public Health Service Grading System^a)

Levels of evidence	
I	Evidence from at least one large randomised, controlled trial of good methodological quality (low potential for bias) or meta-analyses of well-conducted randomised trials without heterogeneity
II	Small randomised trials or large randomised trials with a suspicion of bias (lower methodological quality) or meta-analyses of such trials or of trials with demonstrated heterogeneity
III	Prospective cohort studies
IV	Retrospective cohort studies or case-control studies
V	Studies without control group, case reports, experts opinions
Grades of recommendation	
A	Strong evidence for efficacy with a substantial clinical benefit, strongly recommended
B	Strong or moderate evidence for efficacy but with a limited clinical benefit, generally recommended
C	Insufficient evidence for efficacy or benefit does not outweigh the risk or the disadvantages (adverse events, costs, ...), optional
D	Moderate evidence against efficacy or for adverse outcome, generally not recommended
E	Strong evidence against efficacy or for adverse outcome, never recommended

^aBy permission of the Infectious Diseases Society of America [27].

references

- Jemal A, Simard EP, Dorell C et al. Annual Report to the Nation on the Status of Cancer, 1975–2009, featuring the burden and trends in human papillomavirus (HPV)-associated cancers and HPV vaccination coverage levels. *J Natl Cancer Inst* 2013; 105: 175–201.
- Palefsky JM, Giuliano AR, Goldstone S et al. HPV vaccine against anal HPV infection and anal intraepithelial neoplasia. *N Engl J Med* 2011; 365: 1576–1585.
- Goh V, Gollub FK, Liaw J et al. Magnetic resonance imaging assessment of squamous cell carcinoma of the anal canal before and after chemoradiation: can MRI predict for eventual clinical outcome? *Int J Radiat Oncol Biol Phys* 2010; 78: 715–721.
- Edge SB, Byrd DR, Compton CC. eds. *AJCC Cancer Staging Handbook*, 7th edition. New York, NY: Springer 2010.
- Bartelink H, Roelofs F, Eschwege F et al. Concomitant radiotherapy and chemotherapy is superior to radiotherapy alone in the treatment of locally advanced anal cancer: results of a phase III randomized trial of the European Organization for Research and Treatment of Cancer Radiotherapy and Gastrointestinal Cooperative Groups. *J Clin Oncol* 1997; 15: 2040–2049.
- British HIV Association, British Association of Sexual Health and HIV, British Infection Society. UK National Guidelines for HIV Testing 2008. www.bhiva.org/hivtesting2008.aspx (14 April 2014, date last accessed).
- Oehler-Jänne C, Huguet F, Provencher S et al. HIV-specific differences in outcome of squamous cell carcinoma of the anal canal: a multicentric cohort study of HIV-positive patients receiving highly active antiretroviral therapy. *J Clin Oncol* 2008; 26: 2550–2557.
- Wexler A, Berson AM, Goldstone SE et al. Invasive anal squamous-cell carcinoma in the HIV-positive patient: outcome in the era of highly active antiretroviral therapy. *Dis Colon Rectum* 2008; 51: 73–81.
- Fraunholz I, Rabeneck D, Gerstein J et al. Concurrent chemoradiotherapy with 5-fluorouracil and mitomycin C for anal carcinoma: are there differences between HIV-positive and HIV-negative patients in the era of highly active antiretroviral therapy? *Radiother Oncol* 2011; 98: 99–104.
- Epidermoid anal cancer: results from the UKCCCR randomised trial of radiotherapy alone versus radiotherapy, 5-fluorouracil, and mitomycin. *UKCCCR Anal Cancer*

- Trial Working Party. UK Co-ordinating Committee on Cancer Research. *Lancet* 1996; 348: 1049–1054.
11. Flam M, John M, Pajak TF et al. Role of mitomycin in combination with fluorouracil and radiotherapy, and of salvage chemoradiation in the definitive nonsurgical treatment of epidermoid carcinoma of the anal canal: results of a phase III randomized intergroup study. *J Clin Oncol* 1996; 14: 2527–2539.
 12. Ajani JA, Winter KA, Gunderson LL et al. Fluorouracil, mitomycin, and radiotherapy vs fluorouracil, cisplatin, and radiotherapy for carcinoma of the anal canal: a randomized controlled trial. *JAMA* 2008; 299: 1914–1921.
 13. Peiffert D, Tournier-Rangeard L, Gérard JP et al. Induction chemotherapy and dose intensification of the radiation boost in locally advanced anal canal carcinoma: final analysis of the randomized UNICANCER ACCORD 03 trial. *J Clin Oncol* 2012; 30: 1941–1948.
 14. James RD, Glynn-Jones R, Meadows HM et al. Mitomycin or cisplatin chemoradiation with or without maintenance chemotherapy for treatment of squamous-cell carcinoma of the anus (ACT II): a randomised, phase 3, open-label, 2 × 2 factorial trial. *Lancet Oncol* 2013; 14: 516–524.
 15. Nigro ND, Vaitkevicius VK, Considine B, Jr. Combined therapy for cancer of the anal canal: a preliminary report. *Dis Colon Rectum* 1974; 17: 354–356.
 16. Cummings BJ, Keane TJ, O'Sullivan B et al. Epidermoid anal cancer: treatment by radiation alone or by radiation and 5-fluorouracil with and without mitomycin C. *Int J Radiat Oncol Biol Phys* 1991; 21: 1115–1125.
 17. Kachnic LA, Tsai HK, Coen JJ et al. Dose-painted intensity-modulated radiation therapy for anal cancer: a multi-institutional report of acute toxicity and response to therapy. *Int J Radiat Oncol Biol Phys* 2012; 82: 153–158.
 18. Kachnic LA, Winter K, Myerson RJ et al. RTOG 0529: a phase 2 evaluation of dose-painted intensity modulated radiation therapy in combination with 5-fluorouracil and mitomycin-C for the reduction of acute morbidity in carcinoma of the anal canal. *Int J Radiat Oncol Biol Phys* 2013; 86: 27–33.
 19. Ng M, Leong T, Chander S et al. Australasian Gastrointestinal Trials Group (AGITG) contouring atlas and planning guidelines for intensity-modulated radiotherapy in anal cancer. *Int J Radiat Oncol Biol Phys* 2012; 83: 1455–1462.
 20. Myerson RJ, Garofalo MC, El Naqa I et al. Elective clinical target volumes for conformal therapy in anorectal cancer: a radiation therapy oncology group consensus panel contouring atlas. *Int J Radiat Oncol Biol Phys* 2009; 74: 824–830.
 21. Gunderson LL, Winter KA, Ajani JA et al. Long-term update of US GI intergroup RTOG 98-11 phase III trial for anal carcinoma: survival, relapse, and colostomy failure with concurrent chemoradiation involving fluorouracil/mitomycin versus fluorouracil/cisplatin. *J Clin Oncol* 2012; 30: 4344–4351.
 22. Glynn-Jones R, James R, Meadows H et al. Optimum time to assess complete clinical response (CR) following chemoradiation (CRT) using mitomycin (MMC) or cisplatin (CisP), with or without maintenance CisP/5FU in squamous cell carcinoma of the anus: results of ACT II. 2012 ASCO Annual Meeting. *J Clin Oncol* 2012; 30(suppl): abstr 4004.
 23. Lampejo T, Kavanagh D, Clark J et al. Prognostic biomarkers in squamous cell carcinoma of the anus: a systematic review. *Br J Cancer* 2010; 103: 1858–1869.
 24. Bentzen AG, Balteskard L, Wanderås EH et al. Impaired health-related quality of life after chemoradiotherapy for anal cancer: late effects in a national cohort of 128 survivors. *Acta Oncol* 2013; 52: 736–744.
 25. Bentzen AG, Guren MG, Vonen B et al. Faecal incontinence after chemoradiotherapy in anal cancer survivors: long-term results of a national cohort. *Radiother Oncol* 2013; 108: 55–60.
 26. Sunesen KG, Buntzen S, Tei T et al. Perineal healing and survival after anal cancer salvage surgery: 10-year experience with primary perineal reconstruction using the vertical rectus abdominis myocutaneous (VRAM) flap. *Ann Surg Oncol* 2009; 16: 68–77.
 27. Dykewicz CA. Summary of the guidelines for preventing opportunistic infections among hematopoietic stem cell transplant recipients. *Clin Infect Dis* 2001; 33: 139–144.